

Case report

Late onset fasting triggered thrombosis of internal carotid artery after ovarian stimulation

Ensieh Shahrokh Tehraninejad¹ M.D., Fatemeh Ramezanzadeh¹ M.D., Roya Nasiri² M.D., Mina Jafarabadi¹ M.D., Mohammad Sarafraz Yazdi² M.D.

1 Vali-e-Asr Reproductive Health Research Center, Tehran University of Medical Sciences, Tehran, Iran.
2 Islamic Azad University of Medical Sciences, Mashhad Branch, Mashhad, Iran.

Received: 20 December 2009; accepted: 28 April 2010

Abstract

Background: Ovulation induction and ART may be a newly recognized cause of vascular thrombosis in unusual sites in otherwise healthy women.

Objective: To report a case of thrombosis in right carotid artery 2.5 months after ovarian stimulation for IVF-ET.

Case report: A non pregnant 39-year-old woman, without coagulation disorder and ovarian hyperstimulation syndrome (OHSS). The patient underwent two consecutive cycles of IVF-ET with administration of recombinant FSH and chorionic gonadotropin (10,000 IU) in each cycle. The patient case had thrombosis of the carotid artery with clinical signs 2.5 months later while fasting in Ramadan. Thorough laboratory and imaging investigation revealed no causative factor.

Conclusion: Fasting may trigger thromboembolic complication weeks after ovarian stimulation.

Key words: IVF-ET, Thrombosis, Carotid artery, Fasting.

Introduction

Associated with the increased use of assisted reproductive techniques (ART), there are growing published reports of thromboembolic complications (TEC). The reported TEC after ovarian stimulation comprise both arterial and venous occlusions. In fact ovulation induction and ART may be a newly recognized cause of vascular thrombosis in unusual sites in otherwise healthy women. It has been assumed that the underlying hyper coagulable state characteristic of OHSS due to high serum estrogen and hemoconcentration contributes to vascular thrombosis. Although a majority of TEC occurs with severe OHSS and pregnancy, a few have been described in absence of clinical ovarian hyperstimulation syndrome (OHSS). The magnitude of thrombotic risk during ovarian stimulation cycles is not known.

Prevalence of TEC in patients undergoing ovulation induction is estimated to be 0.08%-0.11% (1,2) up to 0.5% (3) of IVF cycles and can rise up to 4.1% in cases with severe OHSS (4). Of course due to the increasing use of ART the frequency of these complications will also increase.

In this report we present a case of right internal carotid artery thrombosis following failed in vitro fertilization (IVF). This case is unique in that arterial thrombosis occurred in the absence of severe OHSS, pregnancy and thrombophilia with a prolonged latency period after induction ovulation (2.5 months), but in a fasting and dehydration status of patient during Ramadan.

Case report

A 39-year old woman was admitted in neurology ward with the complaint of left sided paresis on 09-28-2008. She had a sudden onset headache not responding to pain killers 6 days before admission. Hemifacial deviation in right

Corresponding Author:

Roya Nasiri, Islamic Azad University of Medical Sciences, Mashhad Branch, Mashhad, Iran.

Email: nasiri.roya1@gmail.com

side and weakness in left upper limb developed 2 days later. The paresis progressed into left lower limb during next day. Headache, nausea and vomiting reagravated the night before admission. Patient reported a 20 day fasting period proceeding to the onset of symptoms. She had a history of 7 years primary infertility due to polycystic ovarian disease and her medical and family histories were unremarkable for systemic and familial disease and thrombophilia. She had the history of two IVF cycles with an interval of three months. In her second cycle of IVF she underwent an ovulation induction cycle with the long luteal protocol. Busereline was given 0.5 mg/day from mid-luteal phase. Gonal-F was administered three ampoules per day from day 3 in next cycle. Follicular growth and serum estradiol level were monitored and on day 11 of cycle, HCG 10.000 IU, I.M. was administered. Trans Vaginal oocyte retrieval was done 36 h after HCG injection under mild I.V. sedation with propofol (2mg/kg). Nine oocytes were picked up and 48h after oocyte retrieval, 4 good quality embryos were transferred transcervically at 06-26-2008. According to the absence of associated clinical signs, sever OHSS was not detected during the cycle. Her last IVF cycle was 2.5 months ago.

At the time of admission, she had normal vital signs (BP) in physical examination, central facial paresis; hemifacial hypoesthesia and reduced pin prick sensation were detected in left side. Also left side deviated hemiparetic gait was observed. Other findings in physical examination were unremarkable. Complete blood counts, liver and renal function tests, serum electrolyte concentrations, blood sugar and lipid profile were all within normal limits. Thrombophilia work up, including protein C, protein S, and antithrombin III deficiencies as well as factor v leiden, prothrombin gene mutation (G 20210A), homocysteinemia, IgG and IgM anti cardiolipin antibodies, lupus anticoagulant, anti DNA (ds), ANA and ANCA, was negative. Carotid color doppler sonography revealed absent arterial flow in right internal carotid artery (RICA) with the impression of RICA thrombosis. The results of echocardiography and brain MRV were within normal limits. Brain computed tomography without contrast and brain MRI revealed left frontoparietal acute ischemia (Figure 1). Digital brain four vessel angiography, applying DSA method, demonstrated tapering and obstruction in the proximal part of RICA (Figure 2). No vascular aberration was found.

Cervical magnetic resonance angiography was in favor of RICA occlusion in the proximal end

with an impression of acute left frontoparietal ischemia due to RICA thrombosis (Figure 3). Anti coagulation using I.V. heparin and aspirin were initiated. The patient made a significant improvement in her neurological condition over the following week and was discharged from the hospital on aspirin and plavix therapy. She continued to improve gradually, and recovered completely within two months. The Institutional Review Board approval for publication was obtained.

Discussion

This is a case report of RICA thrombosis in a PCOS patient whom thorough investigation revealed no causative factor. Prolonged fasting status plus a history of two consecutive IVF-ET cycle 2.5 months ago were the only positive findings. It seems that the incidence of TEC in women undergoing IVF is similar to the risk of venous thrombosis during pregnancy (5) and represents at least a 10-fold increase in baseline risk of TEC in women of reproductive age (6). The peak estradiol concentration in natural menstrual cycle is 200-400 pg/ml but in IVF cycle its level rises about 10-15 fold. It is also known that, in pregnancy, high estrogen levels can tilt the blood coagulation system towards hypercoagulability. Increased risk of intravascular thrombosis during ovulation induction is also due to the high level of estradiol (7), as in the case of TEC associated with the use of OCP or HRT. It is generally believed that sex steroids may induce hypercoagulability but for thromboembolism to evolve, other factors must be present because in many cases the thromboembolic event was diagnosed sometime after the expected peak estradiol concentration (around the time of HCG administration). This hypercoagulability state is related not only to the level of serum estradiol concentration but also to the biochemical changes that occur after ovulation induction with HCG. In IVF cycles after induction of ovulation with HCG, coagulation factors like vWF, Factor II, V, VII, VIII, IX and fibrinogen are elevated (8,9). Estradiol can act directly on vascular walls, diminishing both peripheral arterial and venous wall tone and slowing blood flow (10, 11). Also estradiol can act on circulating monocytes to release tissue factor, thus activating coagulation cascade without overt vessel – wall damage (12).

On the other hand, increased fibrinolytic phenomena indicated by an elevated plasminogen concentration, decreased alpha₂- plasmin inhibitor

and increased concentration of fibrinomers (D dimers), and thrombin – antithrombin complexes have been shown in several studies (13-15). Whether these changes are sufficient by themselves to explain the occurrence of TEC is yet unknown. From published studies performed on women undergoing ovarian stimulation, one can conclude that activation in both the coagulation and fibrinolytic systems do occur, and it appears to be exaggerated with the development of OHSS (14, 16, 17). Besides, we don't have information about the possible contribution of luteal phase support with either progesterone or estrogen after development of pregnancy to an underlying prothrombotic state.

Based on the reviews of reported cases of TEC following ovarian stimulation performed by Chan *et al* (8), Anjali *et al* (18) and Ou *et al* (19), in all but one case (20) thrombosis occurred after HCG administration, and in the majority of cases, IVF was performed.

Approximately 75% of cases were associated with pregnancy, 33% were arterial and 67% were venous in origin. OHSS was reported in 95% of cases with arterial thrombosis and in 70% of women with venous thrombosis. Of the cases of arterial thrombosis more than half involved cerebrovascular events, while for the cases of venous thrombosis the predominant sites were the veins of the neck, upper limb and head veins (71%). Inherited thrombophilia was detected in one – third of the women tested and was more prevalent in the case of venous thrombosis. On the average, arterial thrombosis presented 10.5 days after embryo transfer, and venous thrombotic complications presented 40 days after embryo transfer. In the case of intracranial thromboembolism both arterial and venous in origin the mean onset for clinical presentation was 10.2 days after oocyte retrieval. In a few cases TEC occurred despite heparine prophylaxis (21-24). Based on the existing literature that is confined to case reports some of the risk factors of TEC following ovarian stimulation are OHSS, pregnancy, inherited or acquired thrombophilia, advanced age, diabetes, obesity, hyperhomocysteinemia and past history of thrombosis.

In this patient a complete assessment of TEC risk factors was done. According to the thorough investigation and a negative family history no causative relation was found. The history of doing IVF 2.5 months ago and prolonged fasting period were the lone predisposing factors. The time between ovarian stimulation and onset of arterial thrombosis was 2.5 months which is the longest

interval reported in literature up to now and points to the fact that hypercoagulable state of ART cycles may persist much longer in special circumstances. The patient in present report underwent two subsequent cycles of ART with an interval of 3 months. The first cycle of ART was uneventful and the only prominent difference in patient's medical base after the second cycle was fasting for 20 days just before the onset of neurological signs. Ramadan is the Islamic month of fasting, in which participating Muslims refrain from eating and drinking from dawn until sunset. Due to its dehydration and hemoconcentration state (like OHSS), fasting has been mentioned as one of the risk factors for TEC (25, 26). Unfortunately, we were not able to show dehydration state in this patient, because she had stopped fasting after developing the first neurological signs. In this patient the time of fasting was about 18 hours per day due to long days of summer. It can be interpreted that fasting and dehydration in long hot days of summer may play a causative role in occurrence of TEC in sex hormone induced hypercoagulability state in this patient. Fasting alone does not seem to be the cause as the patient used to practice fasting every year. In this year while fasting after two consecutive cycles of in Vitro fertilization TEC occurred. Even though there was 2.5 months interval between the last IVF cycle and occurrence of TEC, considering absence of other documented risk factors, ruling out the probable synergistic effect of IVF cycle on TEC besides fasting based on estradiol level is an optimistic conclusion. Hyperestrogenism alone is not responsible for the risk of TEC following ART, for thromboembolism to evolve, some other factors must be present. In majority of reported cases the thromboembolic event was diagnosed days to weeks after the expected peak estradiol concentration.

As the exact pathophysiology of TEC following sex steroid induced hypercoagulability is not completely identified, there may be more risk factors not fully detected yet. Up to now it has not been determined that superovulation induced hypercoagulability state how much long lasts? And what are the factors which can cause exaggeration or prolongation of these haemostatic changes? As in practice, prophylactic anticoagulation therapy is continued after ovarian stimulation in high risk subjects. Likewise in high risk pregnant patients for TEC, based on the odds of relative risk factors anticoagulation therapy is continued up to 6-12 weeks of puerperal period despite normal estrogen level after deliver. Notably, given the

multifactorial etiology of TEC following ART, resulting from the synergistic effects between separate predisposing conditions, all women undergoing controlled ovarian stimulation should undergo risk assessment. Prophylactic or therapeutic anticoagulation therapy, minimal ovarian stimulation and avoidance of some predisposing factors (obesity, dehydration, fasting and immobility) should be kept in mind in high risk subjects. Also the patient should be made aware of the risk she is going to undertake for an elective procedure. Some questions that must be answered in future researches are;

- Which population of IVF patients is at risk for TEC?
- How can they be identified before developing thrombosis?
- When should prophylactic anticoagulation be initiated in high risk group? As mentioned before TEC may occur despite prophylactic anticoagulation probably because of late onset of treatment (21-24).
- Finally how long the women at risk should be given heparin if not achieving pregnancy?

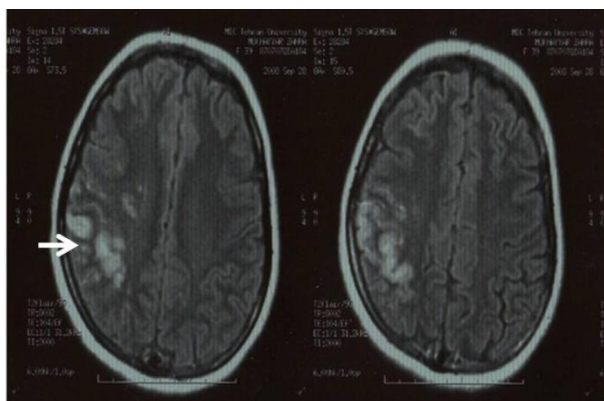


Figure 1. Left frontoparietal acute ischemia in brain MRI.

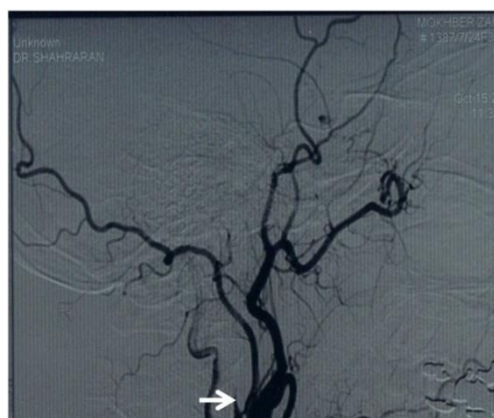


Figure 2. Tapering and obstruction in the proximal part of RICA in Digital brain four vessel angiography applying DSA method demonstrated.

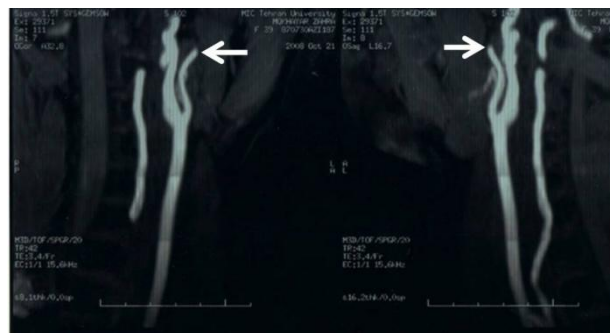

Figure 3. Occlusion in the proximal end of RICA in Cervical magnetic resonance angiography

References

1. Chan WS, Ginsberg JS. A review of upper extremity deep vein thrombosis in pregnancy: unmasking the ‘ART’ behind the clot. *J Thromb Haemost* 2006; 4: 1673-1677.
2. Mara M, Koryntova D, Rezabek K, Kapral A, Drbohlav P, Jirsova S, et al. Thromboembolic complications in patients undergoing in vitro fertilization: retrospective clinical study. *Ceska Gynekol Jul* 2004; 69: 312-316.
3. Grandone E, Colaizzo D, Vergura P, Cappucci F, Vecchione G, Lo Bue A, et al. Age and homocysteine plasma levels are risk factors for thrombotic complications after ovarian stimulation. *Hum Reprod* 2004; 19: 1796-1799.
4. Mára M, Koryntová D, Rezábek K, Kaprál A, Drbohlav P, Jirsová S, Zivný J. [Thromboembolic complications in patients undergoing in vitro fertilization: retrospective clinical study] *Ceska Gynekol* 2004; 69: 312-316.
5. Lindquist P, Dahlback B, Marsal K. Thrombotic risk during pregnancy: A population study. *Obstet Gynecol* 1999; 94: 595-599.
6. Douketis JD, Ginsberg JS, Holbrook A, Crowther M, Duku EK, Burrows RF. A reevaluation of the risk for venous thromboembolism with the use of oral contraceptives and hormone replacement therapy. *Arch Intern Med* 1997; 157: 1522-1530 [Review].
7. Udoff LC, Branch DW. Management of patients with antiphospholipid antibodies undergoing in vitro fertilization. *J Autoimmun* 2000; 15: 209-211.
8. Chan WS, Dixon ME. The “ART” of thromboembolism: A review of assisted reproductive technology and thromboembolic complications. *Throm Res* 2008; 121: 713-726.
9. Baumann P, Diedrich K. Thromboembolic complications associated with reproductive endocrinologic procedures. *Hematol Oncol Clin North Am* 2000; 14: 431-443.
10. Balasch J, Arroyo V, Carmona F, et al. Severe ovarian hyperstimulation syndrome: Role of peripheral vasodilation. *Fertil Steril* 1991; 56: 1077-1083.
11. Colburn P, Buonassisi V. Estrogen-binding sites in endothelial cell cultures. *Science* 1978; 201:817-819.
12. Aune B, Oian P, Osterud B. Enhanced sensitivity of the extrinsic coagulation system during ovarian stimulation for in-vitro fertilization. *Hum Reprod* 1993; 8: 1349-1352.
13. Kodama H, Fukuda J, Karube H, Matsui T, Shimizu Y, Tanaka. Characteristics of blood hemostatic markers in a patient with ovarian hyperstimulation syndrome who actually developed thromboembolism. *Fertil Steril Dec* 1995; 64:1207-1209.
14. Kodama H, Fukuda J, Karube H, Matsui T, Shimizu Y, TanakaT. Status of the coagulation and fibrinolytic

- systems in ovarian hyperstimulation syndrome. *Fertil Steril* 1996; 66: 417-424.
15. Golan A, Ron-el R, Herman A, et al: Ovarian hyperstimulation syndrome: An update review. *Obstet Gynecol Surv* 1989; 44: 430-440.
 16. Ogawa S, Minakami H, Araki S, Ohno T, Motoyama M, Shibahara H, et al. A rise of the serum level of von Willebrand factor occurs before clinical manifestation of the severe form of ovarian hyperstimulation syndrome. *J Assist Reprod Genet* 2001; 18: 114-119.
 17. Rogolino A, Coccia ME, Fedi S, Gori AM, Cellai AP, Scarselli GF, et al. Hypercoagulability, high tissue factor and low tissue factor pathway inhibitor levels in severe ovarian hyperstimulation syndrome: possible association with clinical outcome. *Blood Coagul Fibrinolysis* 2003; 14: 277-282.
 18. Rao AK, Chitkara U, Milki AA. Subclavian vein thrombosis following IVF and ovarian hyperstimulation: a case report. *Hum Reprod* 2005; 20: 3307-3312.
 19. Ou YC, Kao YL, Lai SL, Kung FT, Huang FJ, Chang SY, Chang Chien CC. Thromboembolism after ovarian stimulation: successful management of a woman with superior sagittal sinus thrombosis after IVF and embryo transfer: case report. *Hum Reprod* 2003; 18: 2375-2381.
 20. Ludwig M, Felberbaum RE, Diedrich K. Deep vein thrombosis during administration of HMG for ovarian stimulation. *Arch Gynecol Obstet* 2000; 263: 139-141.
 21. Edris F, Kerner CM, Feyles V, Leung A, Power S. Successful management of an extensive intracranial sinus thrombosis in a patient undergoing IVF: Case report and review of literature. *Fertil Steril* 2007; 88: 705: e9-14.
 22. Hignett M, Spence JE, Claman P. Internal jugular vein thrombosis: a late complication of ovarian hyperstimulation syndrome despite mini-dose heparin prophylaxis. *Hum Reprod* 1995; 10: 3121-3123.
 23. Horstkamp B, Lubke M, Kentenich H, Riess H, Buscher U, Lichtenegger W. Internal jugular vein thrombosis caused by resistance to activated protein C as a complication of ovarian hyperstimulation after in-vitro fertilization. *Hum Reprod* 1996; 11: 280-282.
 24. Mancini A, Milardi D, Di Pietro ML, Giacchi E, Spagnolo AG, Di Donna V, et al. A case of forearm amputation after ovarian stimulation for in vitro fertilization-embryo transfer. *Fertil Steril* 2001; 76: 198-200.
 25. Nelson SM, Greer IA. The potential role of heparin in assisted conception. *Human Reproduction Update* 2008; 14: 623-645. doi:10.1093/humupd/dmn031.
 26. Saadatnia M, Zare M, Fatehi F, Ahmadi A. The effect of fasting on cerebral venous and dural sinus thrombosis. *Neurol Res* 2009; 31: 794-798.

