Iranian Journal of Reproductive Medicine Vol.5. No.3. pp:127-133, Summer 2007

The effects of sodium arsenite on the testis structure and sex hormones in vasectomised rats

Malek Soleimani Mehranjani Ph.D.,Masood Hemadi M.Sc.

Department of Biology, Faculty of Science, University of Arak, Arak, Iran.

Received: *: 16 May 2007* ;accepted: *12August 2007*

Abstract

Background: Sodium arsenite and/ or vasectomy may cause variation in sex hormones which affect pathophysiology of reproductive organs.

Objective: The aim was to investigate the morphological changes in structure of testis and hormonal imbalance in bilateral Vasectomised rats treated with sodium arsenite.

Materials and Methods: Four groups of rats: bilateral vasectomy + sodium arsenite, bilateral vasectomy, sham operated + sodium arsenite and sham operated only were considered, and 8 mg/kg/ day of sodium arsenite was given for 8 weeks to the rats. The total volume of testis, volume of interstitial tissue, volume of seminiferous tubules, diameter of seminiferous tubules and germinal epithelium thickness were evaluated using stereological methods. Hormones were also measured and the results were analyzed using one way ANOVA.

Results: A significant reduction of total volume of testis ($p<0.01$), mean volume of seminiferous tubules ($p<0.002$) as well as germinal epithelium thickness ($p<0.05$) in both vasectomy + sodium arsenite and vasectomy rats was seen compared to sham operated only. In addition a significant reduction of testosterone was observed in vasectomy + sodium arsenite group when compared to the other groups ($p<0.001$). LH level decreased significantly in vasectomy + sodium arsenite when compared to sham operated ones ($p<0.05$).

Conclusion: Vasectomy and treatment with sodium arsenite affect the structure of testis with respect to its volume, volume of seminiferous tubules and thickness of germinal epithelium, which may be due to variation of LH and testosterone level in the rats.

Key words: *Sodium arsenite, Vasectomy, Testis, Sex hormones, Stereology.*

Introduction

Arsenical compounds are environmental toxins with multiple effects in animal and human populations. Human are exposed to arsenic mainly through water, food and drugs. The main source of environmental arsenic exposure in most populations is the drinking water. The frequent uses of arsenic are as herbicides, insecticides, rodenticides and food preservatives (1-3). In addition, investigations have shown that arsenite has toxic effects on the reproductive system which accumulate in the testes, seminal vesicle and the prostate glands; it also causes disorders in the sperms motility (4). Pathological changes of the testes following vasectomy in some cases are due to imbalance in the level of sex hormones (5), on the other hand exposure to sodium arsenite leads to pathological damage in the structure of testes (6) and imbalance of sex hormones (3). From one side, in today's world men undergo surgical vasectomy based on a population control program and in other side people are exposed to arsenite pollution. Thus the question is what will be the cumulative effect of arsenite and vasectomy. The present study was designed to evaluate the effects of arsenite toxicity and vasectomy together on pathological changes of testis using stereological methods and the

Correspondence Author:
Dr Malek Soleimani Mehranjani, Department of biology, Faculty of science, University of Arak, Arak, Iran.
E-mail: m-soleimani@araku.ac.ir

[Downloaded from ijrm.ir on 2024-04-24]

hormones level (LH, FSH and testosterone) in adult Wistar rats.

Materials and methods

Animals

In total 32 male Wistar rats (from Pasture Institute of Iran) with mean body weight of 200± 20 g were randomly divided into 4 groups (n=8) including bilaterally vasectomised, vasectomised + sodium arsenite, sham operated + sodium arsenite and sham operated only. The animals were kept in the animal house of Arak University under 22 ± 2 ^{0}C and photoperiod controlled room (Light 12 h and dark 12 h) with free access to food and sufficient water.

Animal operation

The rats were first anesthetized by using intra peritoneal injection of 10% ketamin (50 mg/kg) along with 2% xylazine (10 mg/kg) (ALFASAN) (5). Then under sterile conditions a split, one centimeter long was made on the sclerotum to reveal the vas deferan duct. After departing its blood vessels, two nodes (0.5 cm apart from each other) one centimeter away from epididim tail, were made using silk tread (0-4) and then the vas deferan duct was cut between the two nodes. Finally the cromster muscle and peritoneal layer were sutured with absorbable tread (0-4) and the skin as well as the fascia layer was also sutured with silk tread (0-4). Sham operation was performed in the same manner except that the vas deferens was neither legated nor divided (7).

Drug treatment

Sodium arsenite was purchased from Merck Company (Germany). Two weeks after vasectomy, Vasectomised + sodium arsenite and sham + sodium arsenite groups were treated orally with sodium arsenite (8 mg/Kg/day) (8, 9) prepared freshly in distilled water just before use. Vasectomised and sham only groups were given only water drinking. The treatment of groups was carried out during 8 weeks after vasectomy (10).

Serum sample collection and tissue preparation

At the end of the treatment (8 weeks), blood sample was collected from abdominal aorta under anesthesia. Heparinized plasma was separated using centrifugation (3000 rpm) and stored at -80 °C to carry out the hormonal-assays. The right testis of rats was taken out then cleaned from epididim and its fatty supportive tissue. The testes were weighed and fixed in 4% formaldehyde solution. To obtain macroscopic slices, tissue was placed in 7% agar gel blocks and slices with 1 mm thickness were made, then using microtome 5 µm thick sections were made and stained using H & E method. Quantitative study including estimation of the total volume of testis (mm^3), volume of interstitial tissue (mm^3), volume of seminiferous tubules, diameter of seminiferous tubules (µm) and its germinal epithelium thickness (µm) were carried out using stereological techniques.

Stereological study

Estimation of the mean total volume of testis and its components based on 12 sections per rat testis were analyzed serologically with a projector (Delux) at final magnification of 64. Statistically it has been proved that 10-12 sections are sufficient for stereologically study (11-13). Images of the sections were projected on a working table and a fine grid of points was superimposed on them. Point counting method using Cavalieri principle was carried out to determine the total volume of testis according to the formula $V = \frac{\sum_{i=1}^{n} p \times a(p) \times t}{M^2}$ Where V stands for absolute volume, a (P) for area of point (grid), t for distance between the sections and M^2 for square of profile magnification.

To obtain volume of the testis components including seminiferous tubules and interstitial tissue, first the volume density (Vv) of them was estimated using BX40 - microscope with a personal computer and a monitor were connected to color camera (DP12) mounted on top of the microscope. The stereological probes were superimposed on the images of the tissue sections viewed on the monitor. The volume density (Vv) was obtained using the formula $Vv = \frac{\sum p(structure)}{\sum p(ref)}$ (11-13).

Where $\sum p(structure)$ indicates the number of points hitting the parameters and $\sum p(ref)$ is the number of points hitting the reference space. The absolute volume of each structure was estimated by the volume density multiplied by the total volume of the testis. For estimating the diameter of seminiferous tubules and its germinal epithelium thickness, the unbiased counting probe was used (14). These were obtained by measuring the length of isotropic line (L0), which is a part of the point-sampled intercept (PSI) method. PSI is an

[Downloaded from ijrm.ir on 2024-04-24]

extremely efficient direct method for measuring the mean volume-weighted particle volume, from single IUR or VUR sections (15, 16).

Hormones (LH, FSH and testosterone) assay

Plasma follicle-stimulating hormone (FSH), lutuneizing hormone (LH) and Testosterone concentration were measured by enzyme linked immunosorbent assay (ELIZA) using ELIZA reader statfax-303 (Awareness comp. USA). LH and FSH concentrations were measured as described in the instructions provided with the kits (RADIM S.P.A. Roma, Italy), where as Testosterone concentration was measured as described in the instruction provided by kits (DRG Diagnostics GmbH, Germany) in which endogenous testosterone of the rats plasma competes with a testosterone horseradish peroxides conjugate for binding to the coated antibody.

Statistical analysis

Quantitative results obtained from different groups of rats were evaluated for statistical differences by one way analysis of variance (ANOVA) and statistical significance was defined at $p<0.05$. Then multiple comparison test (Tukey test) was used to compare data from groups of rats. In addition, the paired sample t-test was used to compare the means of rats body weight.

Results

The mean total volume of testes, interstitial tissue and the seminiferous tubules (mm^3)

The mean total volume of the testis reduced significantly ($p<0.01$) in the Vasectomised rats compared to the sham operated only. Same result was seen when comparing the Vasectomised + sodium arsenite group and the sham operated only group ($p<0.01$), while no significant difference was found between the sham groups (Table I). The mean volume of the interstitial tissue in the sham group treated with sodium arsenite showed a significant decrease compared to the other groups ($p<0.001$) (Table I).

The mean volume of the seminiferous tubules decreased significantly in the bilateral Vasectomised and Vasectomised + sodium arsenite groups compared to the sham ones ($p<0.002$). However no significant difference ($p>0.05$) was found between the sham operated + sodium arsenite and the sham groups (Table I).

Table I. The testis weight (g), total volume of testis (mm^3), volume of interstitial tissue (mm^3) and volume of seminiferous tubules (mm^3) in four different groups of rats (n = 8), 8 weeks after vasectomy operation and treatment with sodium arsenite (8 mg/Kg/day). Values are means ± sd. Means with the same letter code (a,b,c) do not differ significantly from each other (ANOVA, Tukey test, $p>0.05$).

Groups of rats	testis weight (g)	total volume of testis (mm^3)	volume of interstitial tissue (mm^3)	volume of seminiferous tubules (mm^3)
Vasectomised + sodium arsenite	1.3 ± 0.21^{a}	600.6 ± 50.9^{a}	89.9 ± 7^{a}	510.5 ± 43^{a}
bilaterally Vasectomised	1.30 ± 0.23^{a}	584.8 ± 33.5^{a}	98.9 ± 5.3^{a}	485.9 ± 28.4^{a}
sham operated + sodium arsenite	1.33 ± 0.11^{a}	663.4 ± 70.5^{ac}	72.97 ± 7.8^{b}	590.5 ± 62.8^{b}
sham operated	1.45 ± 0.13^{a}	690.4 ± 26.07^{bc}	89.7 ± 3.4^{a}	600.7 ± 22.7^{b}

The mean diameter of the seminiferous tubules and its germinal epithelium thickness (mm)

A significant reduction was found in diameter of the seminiferous tubules in the Vasectomised group when compared to the sham operated only rats ($p<0.01$). While no significant difference was observed between the Vasectomised + sodium arsenite and sham + sodium arsenite groups compare to the sham ones (Table II). Comparing the Vasectomised and Vasectomised + sodium arsenite groups with the sham groups, a significant reduction ($p<0.05$) was detected in the mean thickness of the germinal epithelium, where as no significant difference in the sham + sodium arsenite group and the sham group alone was observed ($p>0.05$) (Table II).

[Downloaded from ijrm.ir on 2024-04-24]

Table II. The diameter of seminiferous tubules and the thickness of the germinal epithelium (μm) in four different groups of rats (n=8), 8 weeks after vasectomy operation and treatment with sodium arsenite (8 mg/Kg/day). Values are means ± sd. Means with the same letter code (a,b,c) do not differ significantly from each other (ANOVA, Tukey test, p>0.05).

Groups	Diameter of the seminiferous tubules (μm)	Thickness of the germinal epithelium (μm)
Vasectomised + sodium arsenite	311.63 ± 17.98 [a]	65.32 ± 1.87 [a]
bilaterally Vasectomised	291.31 ± 31.20 [a b]	61.26 ± 4.05 [a]
sham operated + sodium arsenite	313.04 ± 17.35 [a]	70.17 ± 2.73 [b]
sham operated	334.96 ± 15.87 [a c]	71.64 ± 2.93 [b]

The body and testes weight

The mean testis weight (g) was the same in all of the groups (p>0.05) (Table I). Where the body weight increased significantly in them at the end of the experiment compared to their first body weight (Table III).

Table III. The first and final body weight (b.w), (g) in four different groups of rats, 8 weeks after vasectomy operation and treatment with sodium arsenite (8 mg/Kg/day). values are means ± SD (Paired sample t-test).

Groups	Mean first b.w.(g)	Mean final b.w.(g)	p-value
Vasectomised + sodium arsenite	210.0 ± 15.3	252.83 ± 17. 8	0.001
bilaterally Vasectomised	249.33 ± 9.99	313.33 ± 23.6	0.001
sham operated + sodium arsenite	208. 7 ± 11.05	265 ± 12. 5	0.001
sham operated	215.8 ± 3.91	313.8 ± 12.32	0.001

Histopathological findings

Figure 1a represents the normal structure of seminiferous tuble in control rats. Comparing the structure of testis in different groups of rats showed that the spermatogenic cells had become vacuolated as a result of sodium arsenite treatment which also led to a less compact arrangement of them; it also reduced the number of spermatids (Fig. 1 b).

The above changes were also detected to a more intense following vasectomy along with tubular atrophy (Fig. 1c).

Treatment of Vasectomised rats with sodium arsenite caused more server vacuolation in spermatogenic cells, a looser order in them and also a reduction in number of spermatids (Fig. 1d).

Hormones

Testosterone reduction was highly significant in vasectomised group treated with sodium arsenite (p<0.001) when compared with the results of the sham only and Vasectomised group. Meanwhile, no significant difference (p>0.05) was observed between the testosterone level in sham group and Vasectomised group. In addition, this study showed that there was no significant difference (p>0.05) in the level of FSH in experimental groups compare to sham only ones. Although no significant difference (p>0.05) in the LH level was detected among the groups (vasectomy + sodium arsenite, vasectomy and sham + sodium arsenite), however a significant reduction (p<0.05) was seen when comparing these groups with the sham only rats, as shown in Table IV.

Table IV. The hormones (LH mIU/ml, FSH mIU/ml and Testosterone ng/ml) in different groups of rats (n=8), 8 weeks after vasectomy operation and sodium arsenite treatment (8 mg/kg/day). Values are means ± sd. Means with the same letter code (a,b,c) do not differ significantly from each other (ANOVA, Tukey test, p> 0.05).

Groups	LH	FSH	Testostrone
Vasectomised + sodium arsenite	0.59[a] ± 0.29	0.71[a] ± 0.4	0.94[a] ± 0.31
bilaterally Vasectomised	0.61[a] ± 0.25	0.36[a] ± 0.16	3.05[b] ± 1.93
sham operated + sodium arsenite	0.69[a] ± 0.17	0.68[a] ± 0.48	2.26[bc] ± 0.99
sham operated	2.08[b] ± 1.93	0.60[a] ± 0.32	5.01[bd] ± 2.18

[Downloaded from ijrm.ir on 2024-04-24]

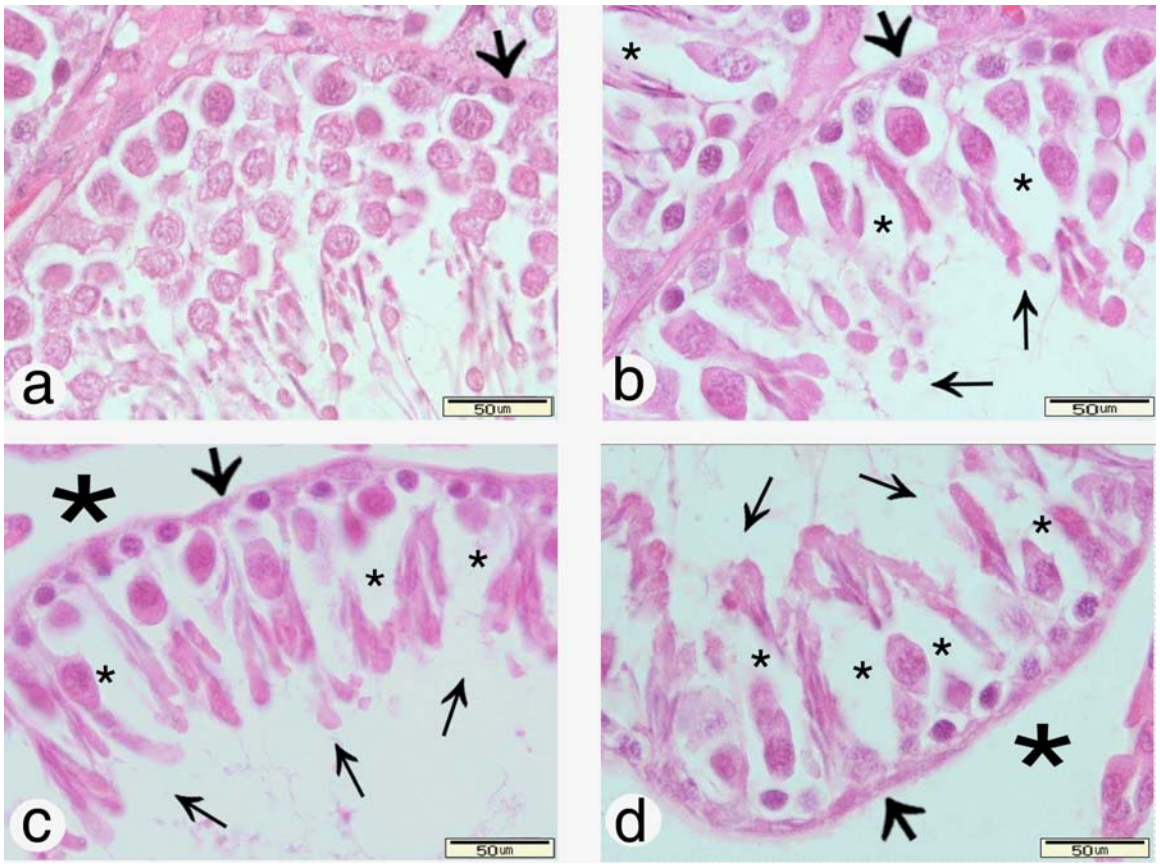

Figure 1. Typical testicular micrographs of 5 µm-thick paraffin –embedded sections stained with H & E method showing the testis structure in different groups of rats. Normal structure of testis in control (sham) rats (a). Vacuolated spermatogenic cells (stars) arranged in a less compact order and smaller number of spermatids (thin arrows) in the testis of sham + sodium arsenite group (b). Atrophied testis with thinner seminiferous tubules, looser arrangement of vacuolated spermatogenic cells, and a less fewer number of spermatids (thin arrows) in the Vasectomised (c) and Vasectomised + sodium arsenite (d) rats, with the exception that vacuolation was more intense in the Vasectomised + sodium arsenite group (small stars). Tubular basement membrane is shown by thick arrows and the intertubular space by big stars.

Discussion

Previous investigations have shown that pathological changes of testis and disorders in male reproductive system following vasectomy are due to different factors including imbalances in the sex hormones (5). On the other hand it has been reported that sodium arsenite also impairs the male reproductive system in mice and rats as well as causing a reduction in sperm count and motility (17). In the present study as the results showed treatment with the sodium arsenite caused reduction in the testosterone and LH level in rats. Reports on sodium arsenite have shown that causes a reduction in sex hormones level including testosterone, LH and FSH (18) confirms the results of this study. Reduction in testosterone level suppresses spermatogenesis and causes a weight loss in testis and also inhibits testicular enzymes (8,18). In our study testosterone reduction in Vasectomised + sodium arsenite group is highly significant, which may be due to a reduction in serum LH level, the main regulating factor in testosterone production by leydig cells of the testis (19).

It seems that there is a cumulative effect between vasectomy and sodium arsenite exposure on the testosterone level production. This raised the expectation that pathological changes in the testis may be more obvious in vasectomised rats following treatment with sodium arsenite. Although comparing the mean total volume of the testis and its weight, the volume of interstitial tissue and seminiferous tubules and its diameter as well as the thickness of germinal epithelium between the vasectomised rats and the Vasectomised + sodium arsenite group showed no significant difference. However we obtained

[Downloaded from ijrm.ir on 2024-04-24]

interesting results by comparing groups. Both vasectomy and exposure to sodium arsenite lead to a 9% reduction in testis weight. Such results have been confirmed by other investigators in vasectomised rats (7,20). Reduction in testis weight has also been seen during chronic treatment with sodium arsenite (3). Comparing both vasectomised and vasectomised + sodium arsenite groups to the sham ones, the mean total volume of the testis, seminiferous tubules and the thickness of the germinal epithelium decreased significantly, while the mean diameter of the seminiferous tubules in vasectomised rats significantly decreased relative to sham group. Our result indicated that treatment with sodium arsenite can influence the structure of testis. Variation in the volume of testis is considered as a notable defect in the male reproductive system due to the oxidative stress caused by sodium arsenite as a consequence of treatment with sodium arsenite which suppresses spermatogenesis (8,21).

Since FSH inhibits normal degeneration of germinal cells (8), its reduction could be a reason for the significant reduction of the volume of testis, seminiferous tubules, and thickness of germinal epithelium found in vasectomised + sodium arsenite rats. In addition reduced concentration of testostrone following treatment with sodium arsenite could be considered as another cause for the degeneration of germinal epithelium which is needed for normal spermatogenesis and maintaining the normal morphology and physiology of the seminiferous tubules (22-24). Testostrone is needed for the continued production of different generation of germinal cells in the seminiferous tubules, therefore reduction of testostrone level may lead to the separation of germinal cells from the epithelium of the seminiferous tubules (25). As other investigators have reported (20), in this study a 13% reduction in the diameter of seminiferous tubules and a significant reduction in the thickness of germinal epithelium were found in the vasectomised rats compared to the sham group. This is probably as a result of testosterone reduction and contraction of the tubules (26,27).

We found a significant reduction in the volume of the interstitial tissue in the sham + sodium arsenite; however vasectomy solely increased the volume of the interstitial tissue up to 11% which could be related to the increased fibrosis of the interstitial and pretubular tissue (28,29). Although it's pathological mechanism is unknown, but it is believed that the resulting oxidative stress causes mast cell penetration into the interstitial tissue which is responsible for the increased fibrosis by stimulating the collagen synthesis (30). Edema has also been mentioned as another factor increasing the volume of interstitial tissue (31). Treatment of sodium arsenite used in this study caused a significant decreases in the interstitial tissue, 22 % increase in the volume of seminiferous tubules, 14 % increase in the mean total volume of testis, 8% increase in the diameter of the seminiferous tubules and 15% increase in the thickness of the germinal epithelium in control + sodium arsenite group compared to the only vasectomised rats. Keeping in mind that sodium arsenite is one of the active chemical compounds that induces oxidative stress and produces reactive oxygen species (ROS) in animal cells which damages intracellular components such as lipids and proteins; this in turn can impair cellular structure (21).

Therefore it is expected that exposure to sodium arsenite following vasectomy should increase the effect of vasectomy on the structure of the testis and sex hormones. Although this dosage of sodium arsenite did not grant this expectation, but it led to a dramatic reduction of the testosterone level and a significant reduction in total volume of testis, volume of seminiferous tubules as well as its germinal epithelium thickness in the vasectomised rats.

Conclusion

We concluded that the reduction of testosterone level may be the main reason of qualitative and quantitative changes observed in this study. We believe that the cumulative effect of vasectomy and sodium arsenite exposure might be a consideration point of the pathological changes, thus we recommend further study with a higher dose of sodium arsenite to reveal the more details of pathological and hormonal changes.

References

1. Liu SX, Athar M, Lippai I, Waldren C, Hei TK. Induction of oxyradicals by arsenic: implication for mechanism of genotoxicity. Proc Natl Acad Sci USA 2001; 8: 1643-1648.
2. Bates MN, Smith AH, Hopenhayn-Rich C. Arsenic ingestion and internal cancers: a review. Am J Epidemiol 1992; 135:462- 476.
3. Jana K, Jana S, Samanta PK. Effect of chronic exposure to sodium arsenite on hypothalamo- pituitary- testicular activities in adult rats: possible an estrogenic mode of action. Repord Biol Endocrinol 2006; 4: 9.
4. Pant N, Murthy RC, Srivastava SP. Male reproductive toxicity of sodium arsenite in mice. Human and Experimental Toxicology 2004; 23: 399-403.

[Downloaded from ijrm.ir on 2024-04-24]

5. Geierhaas B, Bornstein SR, Jarry H, Scherbaum WA, Herrmann M, Pfeiffer EF. Morphological and hormonal changes following vasectomy in rats, suggesting a functional role for Leydig-cell associated. macrophages. Horm Metab Res 1991; 23: 373-8.
6. Pires Das Neves RN, Carvalho F, Carvalho M, Fernandes E, Soares E, Bastos MDL, Pereira MDL. Protective activity of hesperidin and lipoic acid against sodium arsenite acute toxicity in mice . Toxicologic Pathology 2004; 32: 527-535.
7. Ikeda T, Sofikitis N. Bilateral testicular consequences in the unilateral vasectomy of immature rats. Yonago Acta Medica 2000; 43: 1-9.
8. Sarkar M, Chaudhuri GR, Chattopadhyay A, Biswas NM. Effect of sodium arsenite on spermatogenesis, plasma gonadotrophins and testosterone in rats. Asian J Androl 2003; 1: 27-31.
9. Chattopadhyay S, Ghosh S, Chaki S, Debnath J, Ghosh D. Effect of sodium arsenite on plasma levels of gonadotrophins and ovarian steroidogenesis in mature albino rats: duration dependent response. J Toxicol Sci 1999; 24:425-431.
10. Ikeda T, Sofikitis N. Bilateral testicular consequences in the unilateral vasectomy of immature rats. Yonago Acta medica 2000; 43: 1-9.
11. Gundersen H J, Bagger P, Bendtsen TF, Evans SM., Korbo L, Marcussen N, et al. The new stereological tools: disector, fractionator, nucleator and point sampled intercepts and their use in pathological research and diagnosis. APMIS (1988*a*) 96, 857–881.
12. Gundersen HJ, Bendtsen TF, Korbo L, Marcussen N, Moller A, Nielsen K et al. Some new, simple and efficient stereological methods and their use in pathological research and diagnosis. APMIS 1988b; 96: 379-94.
13. Mouton PR. Principles and practices of unbiased stereology: an introduction for bioscientists. The Johns Hopkins University Press. Baltimore/London 2002.
14. Howard CV, Reed MG. Unbiased stereology Three-dimensional measurement in microscopy. Oxford: Bios Scientific Publishers 1998; pp: 143.
15. Gunderson HJG, Jensen EB. Stereological estimation of the volume-weighted mean volume of arbitrary particles observed on random sections. J. Microsc 1985; 138: 127-142.
16. Jensen EB, Gundersen HJG. Fundamental stereological formula based on isotropically oriented probes through fixed points with applications to particle analysis. J Microsc 1989; 153: 249-267.
17. Pant N, Kumar R, Murthy RC, Srivastava SP. Male reproductive effect of arsenic in mice. Biometals 2001; 14: 113-117.
18. Sarkar M, Biswas NM, Ghosh D. Effect of sodium arsenite on testicular and 3beta and 17beta hydroxysteroid dehydrogenase activation in albino rats: dose and duration dependent response. Med Sci Res 1991; 19: 789-793.
19. Chowdhury AK. Dependence of testicular germ cells on hormones: a quantitative study in hypophysectomized testosterone treated rats. J Androl 1979; 82: 331–340.
20. Neaves WB. The rat testis after vasectomy. J Reporod Fert 1974; 40: 39-44.
21. Chang SI, Jin B, Youn P, Park C, Park JD, Ryu DY. Arsenic-induced toxicity and the protective role of ascorbic acid in mouse testis. Toxicology and Applied Pharmacology 2007; 218: 196-203.
22. Sharpe RM, Donachie k, Cooper I. Re-evaluation of the intratesticular level of testosterone required for quantitative maintenance of spermatogenesis in the rat. J Endocrinol 1988; 117: 19–26.
23. Sharpe RM, Maddocks S, Millar M, Saunders PTK, Kerr JB, Mckinnell C. Testosterone and spermatogenesis: identification of stage dependent, androgen- regulated proteins secreted by adult rat seminiferous tubules. J Androl 1992; 13: 172–184.
24. Kim JM, Ghosh SR, Weil ACP, Zirkin BR. Caspase-3 and caspase- activated dioxyribonuclease are associated with testicular germ cell apoptosis resulting from reduced intratesticular testosterone. Endocrinology 2001; 142: 3809–3816.
25. Blanco- Rodriguez J, Martinez- Garcia C. Apoptosis precedes detachment of germ cells from the seminiferous epithelium after hormonal suppression by short-term oestradiol treatment of rats. Int J Androl 1998; 21: 109–115.
26. Shiraishi K, Takihara H, Naito K. Quantitative Analysis of Testicular Interstitial Fibrosis after Vasectomy in Humans. Aktuel Urol 2003; 34: 262-264.
27. Pérez-Marín CC, López R, Domínguez JM, Zafra R. Clinical and pathological findings in testis, epididymis, deferens duct and prostate following vasectomy in a dog. Reprod Dom Anim 2006; 41: 169-174.
28. Jarow JP, Budin RE, Dym M, Zirkin BR, Noren S, Marshall FF. Quantitative pathologic changes in the human testis after vasectomy. A controlled study. N Engl J Med 1985; 313: 1252–1256.
29. Shiraishi K, Takihara H, Naito K. Influence of interstitial fibrosis on spermatogenesis after vasectomy and vasovasostomy. Contraception 2002; 65: 245–249.
30. Yamanaka K, Fujisawa M, Tanaka H, Okada H, Arakawa S, Kamidono S. Significance of human testicular mast cells and their subtypes in male infertility. Hum Reprod 2000; 15: 1543–1547.
31. Raleigh D, O'Donnell L, Southwick GJ, de Kretser DM, McLachlan RI. Stereological analysis of the human testis after vasectomy indicates impairment of spermatogenic efficiency with increasing obstructive interval. Fertil Steril 2004, 81(6):1595-603.

[Downloaded from ijrm.ir on 2024-04-24]