Iranian Journal of Reproductive Medicine Vol.5. No.3. pp:81-88, Summer 2007

Review article

Endometrial nerve fibres in endometriosis

Natsuko Tokushige Ph.D., Moamar al-Jefout M.D., Hilmy Salih M.D., Ian S Fraser M.D.

Department of Obstetrics and Gynaecology, Queen Elizabeth II Research Institute for Mothers and Infants, University of Sydney, Australia.

Received: 15 May 2007;accepted: 5 August 2007

Abstract

Endometriosis is a common gynaecological disease that can cause severe pelvic pain such as dysmenorrhoea and dyspareunia, however the mechanisms by which pain is generated are not well understood. Nerve fibres in endometriotic plaques have been reported by several authors. We have recently demonstrated the presence of unmyelinated sensory nerve fibres (using the pan-neuronal marker PGP9.5) in the functional layer of endometrium in women with endometriosis and a significantly increased nerve fibre density in endometrium and myometrium in women with endometriosis compared with women without endometriosis. Sensory C nerve fibres were only detected in the functional layer of endometrium of women with endometriosis and never in women without endometriosis. This finding is so consistent that it may become an effective means of making the diagnosis of endometriosis. Nerve fibres expressing a range of neuronal markers and an over-expression of nerve growth factor (NGF) and nerve growth factor receptor (NGFRp75) were also demonstrated in peritoneal endometrial plaques in women with endometriosis. Effects of currently available medications for endometriosis on nerve fibres in eutopic endometrium in hormonally treated women have been also studied. This review will describe nerve fibres in eutopic endometrium and ectopic endometriotic plaques in women with endometriosis.

Key words: *Nerve fibres, Endometriosis, Endometrium, Diagnosis.*

Introduction

Endometriosis is an increasingly commonly recognised disease in Western Industrialised Society and is probably also common – but less widely recognised – in the developing world. In spite of a great deal of recent research it is still an enigmatic condition with a high degree of variability from patient to patient – with great variability in age of onset, severity and extent of pain symptoms, occurrence of infertility, anatomical locations , response to treatment and rate of recurrence following treatment. There is a major familial component to the disease and it is likely that a number of different genes contribute to the occurrence and variability of the condition.

In the majority of patients, endometriosis presents with pain symptoms associated with menstruation and pelvic tenderness during sexual intercourse or with a bowel motion. Pelvic pain may also occur erratically at other times, although the classical complaint is of severe, gnawing and dragging pain deep in the pelvis and back which begins in mid-cycle or in the luteal phase and builds up in severity to the onset of bleeding – so-called 'secondary congestive dysmenorrhoea'.

The mechanisms of pain generation are not well understood, although it is recognised that endometriosis is an "inflammatory" condition with the presence of multiple leukocytes of different types in the endometriotic plaques and eutopic

Correspondence Author:
Dr Ian S Fraser **,** Department of Obstetrics and Gynaecology, Queen Elizabeth II Research Institute for Mothers and Infants, University of Sydney, Sydney, NSW 2006, Australia.
E-mail: helena@med.usyd.edu.au

[Downloaded from ijrm.ir on 2024-10-12]

endometrium. Hence, there is the potential for the local production of pain-stimulating molecules within these tissues. Nevertheless, no information is available on pain stimulation pathways or mechanisms for sensory nerve activation in eutopic endometrium or endometriotic plaques.

We have recently made the surprising observation that fine, unmyelinated, sensory nerve fibres are present in the functional layer of eutopic endometrium of women with endometriosis (1, 2). These nerve fibres are also present in ectopic plaques of peritoneal endometriosis (3). By contrast, these nerve fibres are never found in the functional layer of endometrium from women without endometriosis. These observations have the potential to encourage new lines of research into the mechanisms of pain generation and into pain management in endometriosis. They also offer the potential to develop simpler and less invasive techniques for diagnosis of endometriosis.

Discovery of nerve fibres in eutopic endometrium

Small unmyelinated nerve fibres were stained and identified with the highly specific pan-neuronal marker Protein Gene Product 9.5 (PGP9.5) in the functional layer of endometrium in each one of 25 endometrial curettings and 10 full-thickness uterine blocks (from hysterectomy specimens) in women with endometriosis who complained of dysmenorrhoea and a range of related pain symptoms (mean density ± SD, 10 ± 7/mm^2 in curettings, mean density ± SD, 11 ± 5/mm^2 in hysterectomy tissue, respectively)(1). However, no nerve fibres were detected in the functional layer of endometrium from endometrial curettings or full-thickness uterine hysterectomy blocks in any of the women without endometriosis (n = 47 and 35, respectively) (1).

Much more detailed nerve fibres in the functional layer of endometrium in women with endometriosis showed staining with substance P (SP) (a marker for sensory A delta and sensory C nerve fibres), calcitonin gene-related peptide (CGRP)(a marker for sensory A delta and sensory C nerve fibres), vasoactive intestinal polypeptide (VIP) (a marker for sensory A delta, sensory C and cholinergic nerve fibres) and neuropeptide Y (NPY) (a marker for sensory A delta, sensory C and adrenergic nerve fibres), but not with tyrosine hydroxylase (TH) (a marker for adrenergic nerve fibres) or vesicular acetylcholine transporter (VAChT) (a marker for cholinergic nerve fibres) (2). Specific staining for neurofilament (NF) demonstrated myelinated A delta fibres only in the basal layer of endometrium in women with endometriosis, but not in those without endometriosis. Therefore, nerve fibres in the functional layer of endometrium in women with endometriosis were most likely to be all sensory C fibres. Since many inflammatory mediators can be released from endometrium (4, 5), sensory C fibres in the functional layer of endometrium may be sensitised and/or activated by those inflammatory mediators to induce pain symptoms in women with endometriosis.

There was a higher density of nerve fibres stained with PGP9.5 in the basal layer of endometrium and in myometrium in women with endometriosis (mean density ± SD, 18 ± 8/mm^2, 3.3 ± 1.2/mm^2, respectively) than women without endometriosis (mean density ± SD, 0/mm^2, and 0.9 ± 0.8/mm^2, respectively) (1). Many small unmyelinated and large myelinated nerve fibres were present throughout the basal layer of endometrium in women with endometriosis (Figure 1), however small unmyelinated nerve fibres were rarely detected and myelinated fibres were never detected in the basal layer of endometrium in women without endometriosis (1). Obvious thick trunks were seen in the basal layer or at the endometrial-myometrial interface only in women with endometriosis and never in women without endometriosis (1).

Endometrium in women with endometriosis may produce substantial quantities of regulatory molecules with neurotrophic effects (eg nerve growth factor) to induce ingrowth of nerve fibres.

Different types of nerve fibres in eutopic endometrium in women with and without endometriosis

Nerve fibres in the functional layer of endometrium in women with endometriosis only stained with SP, CGRP, VIP and NPY, and were all considered to be sensory C fibres. There was a greater density of nerve fibres of VIP (mean density ± SD, 8.5 ± 2.3/mm^2) and NPY (9.6 ± 2.8/mm^2) (Figure 2) than SP (mean density ± SD, 1.0 ± 0.2/mm^2) and CGRP (mean density ± SD, 1.7 ± 0.4/mm^2)(2). Nerve fibres in the basal layer of endometrium in women with endometriosis were stained with SP, CGRP, TH, VIP, NPY and NF but not with VAChT. Therefore, nerve fibres in the basal layer of endometrium in women with endometriosis were most likely to be a mixture of sensory A delta, sensory C and adrenergic fibres (2). Nerve fibres in the basal layer of endometrium in women without endometriosis were stained

[Downloaded from ijrm.ir on 2024-10-12]

with SP, CGRP, VIP and NPY but not NF, TH or VAChT. Therefore, nerve fibres in the basal layer of endometrium were most likely to be sensory C fibres with some myelinated, sensory A delta fibres (2). Nerve fibres in myometrium were stained with SP, CGRP, TH, VAChT, VIP and NPY in both women with and without endometriosis but the density was much less in those without endometriosis (2). Sensory C fibres in the functional layer of endometrium and adrenergic fibres in the basal layer of endometrium were present only in women with endometriosis and these nerve fibres may be associated with generating pain symptoms in women with endometriosis.

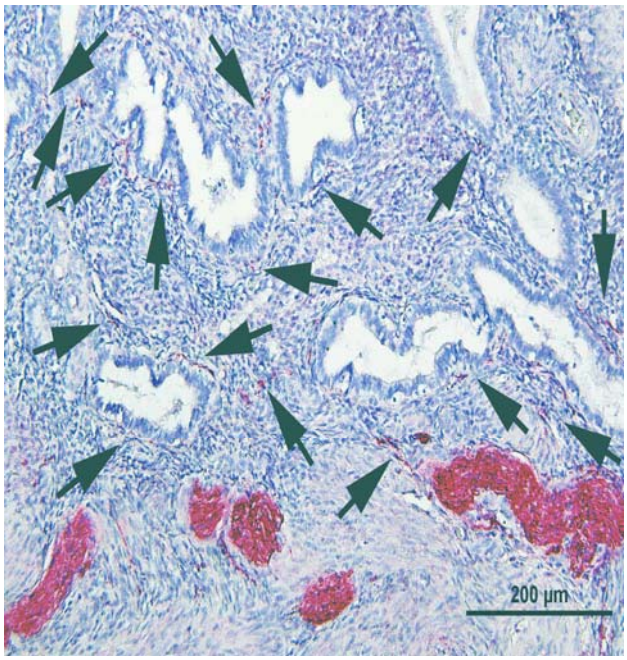

Figure 1. Nerve fibres in the basal layer of endometrium and at the endometrial-myometrial interface from a woman with endometriosis stained with PGP9.5 (magnification x200).

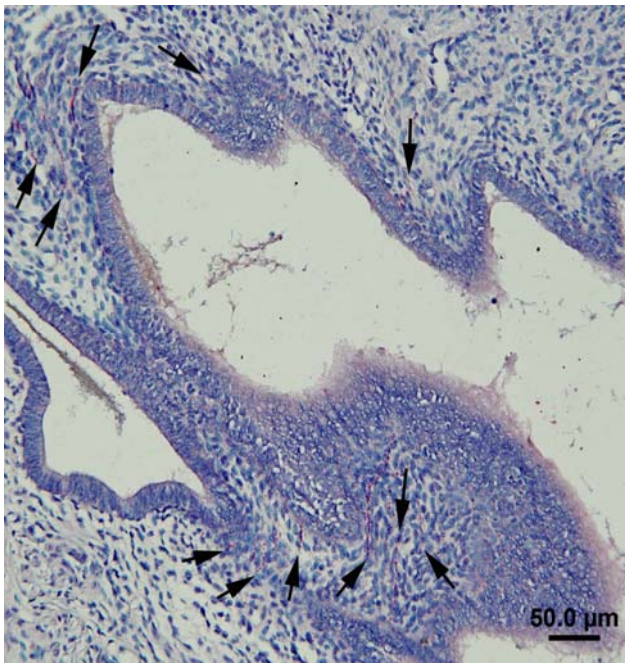

Figure 2. The functional layer of endometrium from a woman with endometriosis (magnification x200). Arrows denote tiny NPY-positive nerve fibres.

[Downloaded from ijrm.ir on 2024-10-12]

Effects of currently available drugs for treatment of endometriosis on endometrial nerve fibres

Currently available drugs to treat women with endometriosis-associated pain include danazol, gonadotropin-releasing hormone (GnRH) analogues, combined oral contraceptives (COCs) and progestogens (6) that can suppress endogenous oestrogen and progesterone production and local hormone action. Nerve fibre density in the functional (n = 27) and basal layers (n = 19) of endometrium and myometrium (n = 19) in hormonally treated women with endometriosis was significantly reduced compared with 10 untreated women with endometriosis (data not published). The density of nerve fibres in the functional and basal layers of endometrium (mean density ± SD, 0.2 ± 0.7/mm^2, 0.9 ± 1.3/mm^2, respectively) and myometrium (1.5 ± 0.8/mm^2) in hormonally treated women with endometriosis was much lower than that of functional and basal endometrium (11 ± 5/mm^2, 18 ± 8/mm^2, respectively; $p<0.001$) and myometrium (3 ± 1/mm^2)(Table I) in women with endometriosis who were not on hormone treatment. Nerve fibres in the functional and basal layers of endometrium in untreated women with endometriosis were stained with SP, CGRP, VIP and NPY, and SP, CGRP, VIP, NPY, NF and TH and respectively (Table I). However, after hormonal treatment, the small number of residual nerve fibres in the functional layer in women with endometriosis only stained with VIP and NPY, and in the basal layer with SP, CGRP, VIP and NPY, (Table I). Nerve growth factor (NGF)(Figure 3) and nerve growth factor receptor 75 (NGFRp75) were over-expressed in endometrium in untreated women with endometriosis, however NGF and NGFRp75 were only very weakly expressed in endometrium in hormonally treated women with endometriosis (data not published). Since oestrogen and progestogen can regulate neurotrophin (7, 8), hormonal therapies for endometriosis may decrease neurotrophin production, resulting in reduced nerve fibre density in endometrium and myometrium in women with endometriosis. This may contribute significantly to the beneficial effect of hormonal therapies on symptoms.

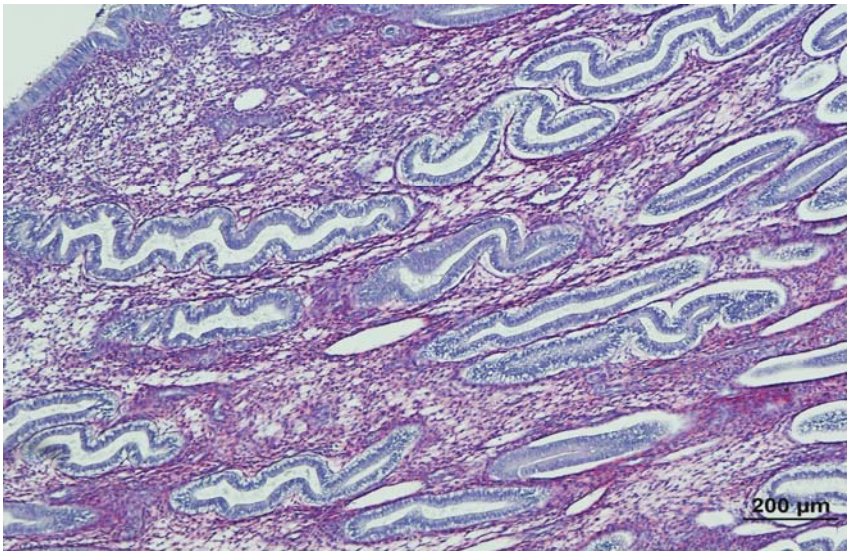

Figure 3. Expression of nerve growth factor in endometrium from a woman with endometriosis who was not on hormonal treatment (magnification x100).

Nerve fibres in peritoneal endometriotic plaques

Peritoneal endometriotic plaques are probably an important source of pain stimuli in many women with endometriosis (9-11) and several researchers have investigated the presence of nerve fibres in endometriotic plaques (3, 12-14). Nerve fibres in endometriotic plaques were stained with SP, CGRP and vesicular monoamine transporter (12), transforming growth factor β1 (TGFβ1)(13) and neurofilament (14). In our study, there was a greater density of nerve fibres stained with PGP9.5 in peritoneal endometriotic plaques in women with endometriosis (mean density ± SD, 16.3 ± 10.0/mm^2) than normal peritoneum in women without endometriosis (mean density ± SD, 2.5 ± 1.3/mm^2), and nerve fibres were a mixture of sensory A delta, sensory C, adrenergic

[Downloaded from ijrm.ir on 2024-10-12]

and cholinergic fibres (3). Nerve fibres were present in greater concentration near endometriotic glands and large amounts of NGF were secreted near endometriotic glands (3). Over-expression of NGF may increase the number of nerve fibres, and many inflammatory mediators released from endometriotic plaques can directly or indirectly sensitise sensory nerve fibres to cause pain symptoms. Since absence of nerve fibres in the functional layer of endometrium after hormonal therapy was not always associated with complete alleviation of pain symptoms in women with endometriosis, there is a need for further investigation of the ways in which hormone therapies for endometriosis can affect nerve fibre density and function in endometriotic plaques.

Table I. A quantitative assessment of nerve fibre density stained with PGP9.5 in endometrium and myometrium in hormonally treated and untreated women with endometriosis.

Variables	Hormonally treated women with endometriosis	Untreated women with endometriosis
Area	Endometrial Functional layer	
Number of specimens	27	10
Number of specimens with positive staining with PGP9.5	3	10
Total nerve fibre density (mean ± SD/mm^2) stained with PGP9.5	0.2 ± 0.7	11 ± 5 (p<0.001)
Positive staining with different neurotransmitter markers	VIP, NPY	SP, CGRP, VIP, NPY
Area	Endometrial Basal layer	
Number of specimens	19	10
Number of specimens with positive staining with PGP9.5	11	10
Total nerve fibre density (mean ± SD/mm^2) stained with PGP9.5	0.9 ± 1.3	18 ± 8 (p<0.001)
Positive staining with different neurotransmitter markers	SP, CGRP, VIP, NPY	SP, CGRP, TH, VIP, NPY
Area	Myometrium	
Number of specimens	19	10
Number of specimens with positive staining with PGP9.5	19	10
Total nerve fibre density (mean ± SD/mm^2) stained with PGP9.5	1.5 ± 0.8	3 ± 1 (p<0.001)
Positive staining with different neurotransmitter markers	SP, CGRP, TH, VAChT, VIP, NPY	SP, CGRP, TH, VAChT, VIP, NPY

Concept of endometriosis as an endometrial disease

A great deal of recent research has demonstrated multiple differences in function within the eutopic endometrium of women with endometriosis compared with women who do not have this disease (15). These differences include changes in expression of structural, metabolic and immune cellular proteins such as cytokeratins, integrins, heat shock proteins, actin, intercellular adhesion molecules, apoptosis proteins, transcription factors and a range of other immune and structural proteins (15-17). We have demonstrated differential expression of 119 out of 820 identified endometrial proteins in women with endometriosis compared with women without endometriosis (15).

More recently, it has been demonstrated that angiogenic activity is increased in the eutopic endometrium of endometriosis sufferers (18) and this appears to correlate with angiogenic activity in the typical peritoneal endometriotic 'flare' lesions (19). This may provide a contributory mechanism to the vascularisation and growth of new endometriotic plaques. Our own recent observations of unmyelinated sensory nerve fibres

[Downloaded from ijrm.ir on 2024-10-12]

in eutopic endometrium (which are not present in "normal" endometrium) provide the first evidence of a reliable structural difference between endometriotic eutopic endometrium and "normal" endometrium. This provides the possibility of reliable diagnosis of endometriosis through an endometrial biopsy (20), and this is discussed in detail below.

The presence of these fine nerve fibres in the functional layer of endometrium raises many questions about their origins. Does their presence precede the development of pain symptoms? Does their presence precede the development of symptomatic endometriotic peritoneal plaques? Could the detection of these nerve fibres in endometrial biopsies be used to detect those women (especially adolescents from families with a strong history of endometriosis) who are predisposed to the disease, before it develops? Are these endometrial and myometrial nerve fibres important in mediating spasmodic "uterine contraction" pain in women before and after they develop typical endometriosis? Are the nerve fibres in endometriotic plaques important in mediating the typical deep pelvic, congestive, dragging peri-menstrual pain?

The dramatically increased expression of nerve growth factor and nerve growth factor receptor in eutopic endometrium and in endometriotic plaques suggests that this abnormality may precede the growth of fine nerve fibres into these tissues. Hence, this could be an important primary abnormality within eutopic endometrium before the condition recognised as endometriosis actually develops.

Adolescent endometriosis and endometrial nerve fibres

Endometriosis has long been considered as a disease of women over the age of 20 years. However, recent data demonstrate a higher than expected incidence in teenagers (21). Endometriosis has been reported in young girls, even before their menarche (22).

It has been reported that these adolescent women with endometriosis have had uterine contractions with higher frequency, amplitude and basal pressure tone during their menstrual period than expected (23).

The expression of small unmyelinated nerve fibres in both basal and functional layers of the endometrium (1,2) of these young women may have played a role in producing these dynamic changes in the uterus. Furthermore, these changes in intensity of myometrial contractions may fully or partly contribute to the development of pelvic pain symptomatology. The multiplicity of molecular and cellular abnormalities demonstrated in the eutopic endometrium of women with endometriosis (16-18) suggests that primary abnormalities in this tissue may have a role in the genesis of endometriosis and perhaps even in the genesis of symptoms.

These young women with endometriosis frequently present with severe spasmodic central pelvic pain (of presumed uterine origin) which begins at or soon after menarche, and which later develops into a more widespread dragging type of deep pelvic pain and backache with the later development of typical peritoneal endometriosis. We believe that these nerve fibers which are present in the functional layer of endometrium of women with endometriosis, may have been present from before the development of typical endometriosis, having a role in atypical spasmodic pain symptomatology before the onset of the typical peritoneal disease. In these cases, the more extensive but dragging and congestive pelvic pain appearing with the onset of endometriosis can be attributable to more widespread disease involving the pelvic peritoneum and ovaries.

The presence of these nerve fibers in endometrium may be incorporated into a diagnostic tool using endometrial biopsy in the diagnosis of endometriosis in these young girls. This method will be less invasive, less costly and less demanding for these young women compared to more invasive laparoscopy and peritoneal biopsy, which currently remains the gold standard in the diagnosis of endometriosis.

From these data, we hypothesize that in these adolescent girls there may have been a primary inherited abnormality in the endometrium which may have been present well before the onset of typical endometriosis. We also believe that this primary abnormality in the endometrium may have implications for aetiology, pathophysiology, diagnosis and treatment of endometriosis in these young girls.

Endometrial biopsy for diagnosis of endometriosis

For many years, clinicians have been searching for the ideal means of making a definite diagnosis of endometriosis. Laparoscopy with histological confirmation is the current gold standard for endometriosis diagnosis. Yet, as a surgical procedure, laparoscopy still has some risks of injuring vessels or abdominal organs and because of the invasiveness of the procedure there is often a

[Downloaded from ijrm.ir on 2024-10-12]

delay before it is contemplated. Moreover, visual inspection of the pelvis also has limitations, particularly for the diagnosis of early peritoneal and deep endometriotic lesions which may not be obvious.

A further problem is the inter-observer variability in assessing atypical lesions. Biopsy is often needed for confirmation. It is not surprising that considerable efforts are being made to improve diagnosis by other means with minimal risks and lower cost.

Based on the novel finding of the unique presence of small nerve fibres in the functional layer of endometrium of women with endometriosis; we conducted a pilot study to explore the possibility of using endometrial biopsy with a suction-enhanced Endosampler to detect endometrial small nerve fibres using immunohistochemistry with the specific pan-neuronal marker PGP9.5. We found that carefully collected endometrial biopsy has 100% specificity and 100% sensitivity in detecting endometriosis when compared with laparoscopy and peritoneal biopsy (20).

Endometrial biopsy is a less invasive procedure than laparoscopy and can usually be achieved without general anesthesia or strong analgesics. It may be useful for the early diagnosis of endometriosis in an outpatient setting. A special target group could be the adolescents with spasmodic dysmenorrhea or atypical pelvic pain and a strong family history of endometriosis, a group in whom delay in diagnosis is typically greater than older women. An endometrial biopsy may enable clinicians to make a more definitive early diagnosis and initiate early therapy. This shortening of diagnosis time will have positive impact on patient's quality of life and help to protect their future fertility.

Conclusions

This novel observation of fine unmyelinated sensory nerve fibres, capable of mediating pain, in the functional layer of eutopic endometrium of women with endometriosis and in ectopic endometriotic plaques, has opened up a whole new field in the study of mechanisms of symptom development and expression in this condition. The observation also provides the potential for easier and earlier diagnosis. The linking of proteomic and genetic studies should also allow the identification of new mechanisms underlying the development, progression, variability and symptomatology of endometriosis.

Acknowledgements

The authors are grateful to Professor Peter Russell for specialised histopathology advice and for blinded assessment of histology.

References

1. Tokushige N, Markham R, Russell P, Fraser IS. High density of small nerve fibres in the functional layer of the endometrium in women with endometriosis. Hum Reprod 2006; 21: 782-787.
2. Tokushige N, Markham R, Russell P, Fraser IS. Different types of small nerve fibers in eutopic endometrium and myometrium in women with endometriosis. Fertil Steril 2007; (In press).
3. Tokushige N, Markham R, Russell P, Fraser IS. Nerve fibers in peritoneal endometriosis. Hum Reprod 2006; 21:3001-3007.
4. Mantyh PW. Neurobiology of substance P and the NK1 receptor. J Clin Psychiatry 2002; 63 Suppl 11:6-10.
5. Schaible HG, Ebersberger A, Von Banchet GS. Mechanisms of pain in arthritis. Ann NY Acad Sci 2002; 966:343-354.
6. Amsterdam LL, Gentry W, Jobanputra S, Wolf M, Rubin SD, Bulun S. Anastrazole and oral contraceptives: a novel treatment for endometriosis. Fertil Steril 2005; 84: 300-304.
7. Bjorling DE, Beckman M, layton MK, Wang ZY. Odulation of nerve growth factor in peripheral organs by oestrogen and progesterone. Neuroscience 2002; 110:155-167.
8. Krizsan-Agbas D, Pedchenko T, Hasan W, Smith PG. Oestrogen regulates sympathetic neurite outgrowth by modulating brain derived neurotrophic factor synthesis and release by the rodent uterus. Eur J Neurosci 2003;18: 2760-2768.
9. Palter SF, Duleba A, Zreik T, DiStasio C, Mandel T, Guarnaccia M, Polcz T, Amesse L, Olive DL. Office Microlaparoscopy Under Local Anesthesia. J Am Assoc Gynecol Laparosc 1996; 3: S38.
10. Almeida ODJr, Val-Gallas JM. Conscious pain mapping. J Am Assoc Gynecol Laparosc 1997;5: 587-590.
11. Demco L. Mapping the source and character of pain due to endometriosis by patient-assisted laparoscopy. J Am Assoc Gynecol Laparosc 1998; 5: 241-245.
12. Berkley KJ, Dmitrieva N, Curtis KS, Papka RE. Innervation of ectopic endometrium in a rat model of endometriosis. Proc Natl Acad Sci U S A 2004; 101: 11094-11098.
13. Tamburro S, Canis M, Albuisson E, Dechelotte P, Darcha C, Mage G. Expression of transforming growth factor beta1 in nerve fibers is related to dysmenorrhea and laparoscopic appearance of endometriotic implants. Fertil Steril 2003;80: 1131-1136.
14. Tulandi T, Felemban A, Chen MF. Nerve fibers andhistopathology of endometriosis-harboring peritoneum. J Am Assoc Gynecol Laparosc 2001; 8: 95-98.
15. Ten Have S, Fraser IS, Markham R, Lam A, Matsumoto I. Proteomic analysis of protein expression in the eutopiuc endometrium of women with endometriosis. Proteomics 2007; (In press).
16. Lessey BA, Castelbaum AJ, Sawin SW, Buck CA, Schinnar R, Bilker W, Strom BL. Aberrant integrin

[Downloaded from ijrm.ir on 2024-10-12]

expression in the endometrium of women with endometriosis. J Clin Endocrinol Metab1994;79:643-649.
17. Ota H, Igarashi S, Hatazawa J, Tanaka T. Distribution of heat shock proteins in eutopic and ectopic endometrium in endometriosis and adenomyosis. Fertil Steril 1997;68:23-28.
18. Healy DL, Rogers PA, Hii L, Wingfield M. Angiogenesis: a new theory for endometriosis. Hum Reprod Update 1998;4:736-740.
19. Jansen RPS, Russell P. Non-pigmented endometriosis: clinical, laparoscopic and pathologic definition. Am J Obstet Gynecol 1986;155:1154-1159.
20. Al-jefout M, Andreadis N, Tokushige N, Markham R, Fraser IS. A pilot study to evaluate the relative efficacy of endometrial biopsy and full curettage in making a diagnosis of endometriosis by the detection of endometrial nerve fibers. Am J Obstet Gynecol 2007;(In press).
21. Bourdel N, Matsusaki S, Roman H, Lenglet Y, Botchorischvili R, Mage G, Canis M . Endometriosis in teenagers. Gynecol Obstet Fertil 2006;34:727-734.
22. Marsh EE, Laufer MR. Endometriosis in premenarcheal girls who do not have an associated obstructive anomaly. Fertil Steril 2005; 83: 758-760.
23. Bulletti C, De Ziegler D, Polli V, Del Ferro E, Palini S, Flamigni C. Characteristics of uterine contractility during menses in women with mild to moderate endometriosis. Fertil Steril 2002;77:1156-1161.

[Downloaded from ijrm.ir on 2024-10-12]