

A case report of Generalized uterine arteriovenous malformation after molar pregnancy in an infertile woman

Firoozeh Ahmadi M.D., Somayeh Moukhah M.Sc.

Department of Reproductive Imaging, Reproductive Biomedicine Research Center, Royan Institute for Reproductive Biomedicine, ACECR, Tehran, Iran.

Corresponding Author:

Firoozeh Ahmadi, Royan Institute, Number 12, East Hafez Avenue, Bani Hashem Street, Resalat high way, Tehran, Iran. P.O. Box: 1665659911.

Email: dr.ahmadi1390@gmail.com

Tel: (+98) 9121503522

Received: 4 April 2017

Revised: 8 June 2017

Accepted: 16 November 2017

Abstract

Background: Uterine arteriovenous malformation (UAVM) is a rare vascular condition in reproductive age presented mostly with bleeding. Although this malformation is infrequent, it is potentially life-threatening. Transvaginal Doppler ultrasonography is a widely available, noninvasive and excellent diagnostic method.

Case: The case is a 30-yr-old woman with a history of eight-yr infertility following intrauterine insemination treatment, she had a molar pregnancy. Despite methotrexate treatment, there was persistent vaginal bleeding. Assessment of this patient was done with transvaginal sonography and color Doppler. According to suspicious appearances, angiography was planned for confirmation of UAVM.

Conclusion: UAVM is one of the molar pregnancy complications. The first step for diagnosis of UAVM is transvaginal ultrasonography and color Doppler assessment. Embolization is the best treatment for women who intend to preserve fertility.

Key words: Color doppler ultrasonography, Embolization, Molar pregnancy, Arteriovenous malformation.

Introduction

Uterine arteriovenous malformation (UAVM) is known as a direct connection of the arterial system to the venous system, without contribution of capillary vessels (1). This vascular abnormality is rare as the review of literature shows the incidence UAVM is 0.10%. The first case was presented in 1926 (2). This malformation is considered as local or generalized lesions. UAVM classifies to congenital and acquired. Occurrence of acquired UAVM is more common than congenital type that resulted from some situations such as "gestational trophoblastic disease, pelvic trauma, surgical procedures (cesarean section, curettage), cervical or endometrial carcinoma, infection and exposure to diethylstilbestrol" (3).

Nowadays, diagnosis of UAVM is possible with noninvasive methods including transvaginal ultrasound and color Doppler. Although transvaginal ultrasound makes with better quality and be considered as the first step for assessment of women with vaginal bleeding, these ultrasound images are nonspecific and assist commonly to the differential diagnosis of UAVM from the other conditions such as gestational trophoblastic

disease and retained product of conception (4, 5). It was shown that color Doppler is a preferable and confident method for initial diagnosis of UAVM (6-8). Therefore, it is suggested to confirmation of transvaginal ultrasound finding with color Doppler for the increased accuracy (4, 5). However, angiography an invasive method for diagnosis of UAVM. It is a gold standard for definitive detection of UAVM (5, 9). Embolization is the best treatment for women who intend to preserve fertility.

In the current case report, the pregnant woman with a history of infertility who developed UAVM following a molar pregnancy is presented. Oral consent had been obtained from the patient before the interview.

Case report

In February 2008, a 30-yr-old woman, presented at the infertility clinic of Reproductive Biomedicine Research Center of Royan Institute (Tehran, Iran). Her chief complaint was 8-yr of old infertility with tubal factor and also vaginal bleeding. In obstetrics and gynecologic history, she had done laparoscopic operation 3 yr ago for endometriosis treatment. Moreover, intrauterine insemination was done that

resulted in a GTD and methotrexate was prescribed for her but due to severe bleeding the patient underwent three curettages. She had uterine bleeding with negative beta-Human chorionic gonadotropin levels, therefore transvaginal sonography was done and we detected numerous echo-free tubular spaces in anterior myometrium ("spongy" myometrium echo texture) with normal endometrium (Figure 1).

According to these suspicious appearances, color Doppler was done and mosaic patterns of color signals within myometrium cystic spaces with high-velocity flow was seen and all cystic spaces fill with flow (Figure 2A, 2B, 3). These features were suspected us to UAVM and angiography

approved it (Figure 4A, 4B). Since the patient desired to preserve her fertility, embolization was done and following in vitro fertilization (IVF) procedure she got pregnant and terminated successfully pregnancy that resulted to birth a girl baby in 5 yr ago.

Albeit embolization, vaginal bleeding continued. After transvaginal ultrasound and also color Doppler assessments the UAVM was persistent. The remarkable note is that although embolization was done for fifth times during 7 yr ago and also the UAVM was durable, the patient has got pregnant afterward the second time IVF and this pregnancy resulted to birth a boy baby with weight 2,650 gr.

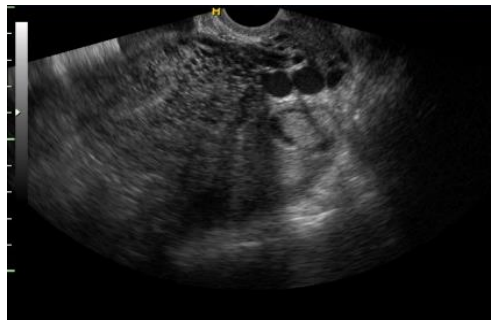

Figure 1. Transverse transvaginal ultrasound (TVUS) shows multiple small anechoic spaces in the anterior myometrium producing a "spongy" myometrial echotexture

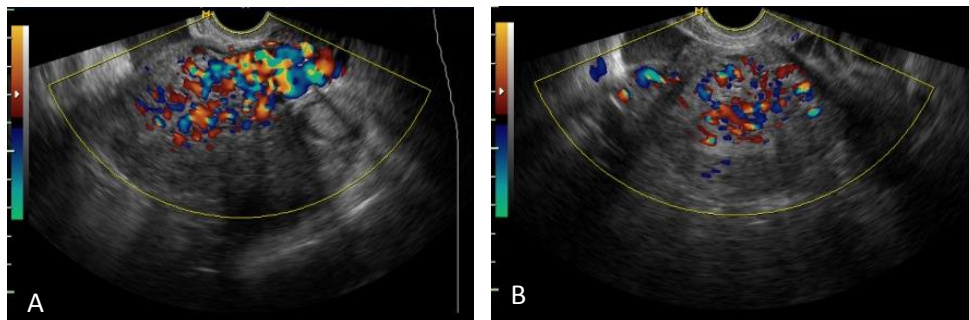


Figure 2. A (Sagittal view) and 2 B (Transverse view). Color Doppler ultrasound in this case shows a mosaic flow within the tubular structure with color aliasing.

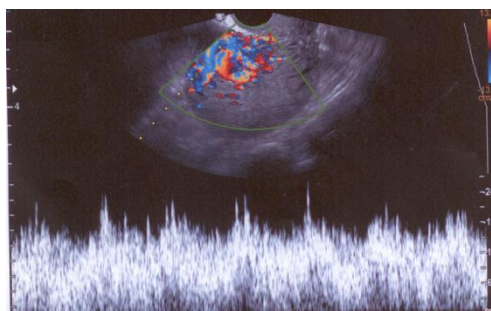


Figure 3. Spectral Doppler ultrasound shows high velocity and low-resistance flow with little variation between systolic and diastolic velocities, compatible with a uterine AVM.

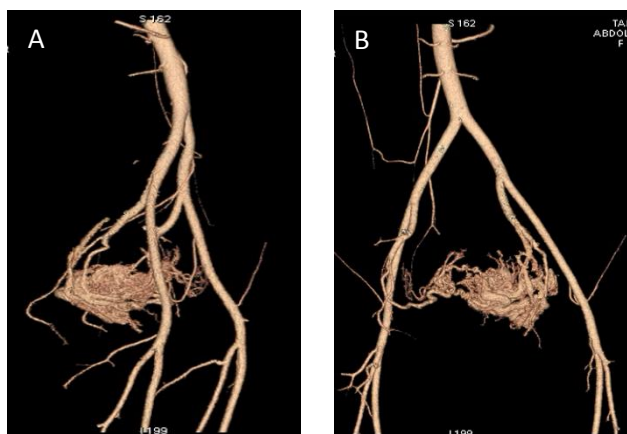


Figure 4. A, B. Enlargement of right uterine arteries has been showed and all typical angiographic findings of uterine confirmed AVMs.

Discussion

UAVM has various clinical presentations from an asymptomatic patient to life-threatening condition, but the most prevalent symptom is periodical and severe vaginal bleeding that often occurs in the reproductive age of a woman (10, 11). We reported an acquired UAVM that was presented with genital bleeding following the gestational trophoblastic disease. Farias *et al* presented a similar case with abnormal genital bleeding (12). Considering that ultrasonography is the first-step for imaging assessment in most studies, we planned a transvaginal sonography (12-14). Commonly UAVM appearance in grayscale sonography contains an ill-defined and homogeneous mass with multiple myometrial and endometrial hypoechoic cystic or tubular-like structures of varying sizes (15).

In our ultrasonography assessment, we found the mix echo pattern with several echo-free cystic lesions in the anterior myometrium. These sonographic features are seen in the other diseases such as gestational trophoblastic disease, retained conception products. This finding is supported in other studies (4, 12, 15, 16). In color Doppler assessment of UAVM, a cystic or tubular space has vascular nature with the low-resistance and high-velocity stream (15). The accurate diagnosis of these lesions is angiography of pelvic (2). Although the role of MRI was emphasized in Farias *et al* study, MRI is an expensive and time-consuming method. Despite MRI finding, confirmation of angiography is necessary for treatment of UAVM.

There are different kinds of methods for management of UAVM based on the age of women, desire for future fertility and severity of bleeding such as hysterectomy, surgical removal of AVM, laparoscopic bipolar coagulation, medical therapy with combined oral contraceptives and embolization (17). To aggravate the bleeding occurrence, curettage is not a suitable management for UAVM therapy. For the woman in the reproductive age and intended to preserve fertility, the best option for treatment is embolization.

Conclusion

Nowadays, the first step for diagnosis of UAVM is noninvasive methods such as transvaginal ultrasound and color Doppler, but angiography is an invasive method for diagnosis of UAVM. In addition, it is a gold standard for definitive detection of UAVM. Embolization is the best treatment for women who intend to preserve fertility. The remarkable note is that although embolization was done for several times, the UAVM was durable and this woman is pregnant currently afterward the second-time IVF was done.

Acknowledgement

The authors appreciate the cooperation and consent of the patient who participated in this study.

Conflict of interests

The author declares that he has no competing interests.

References

1. Belfort P, Braga A, Freire NS. Malformação arteriovenosa uterine após doença trofoblástica gestacional. *Rev Bras Ginecol Obstet* 2006; 28: 112-121.
2. Fleming H, Ostor AG, Pickel H, Fortune DW. Arteriovenous malformations of the uterus. *Obstet Gynaecol* 1989; 73: 209-214.
3. Shaaban AM, Menias CO, Tubay MS, Rezvani M, Arouk El Sayed RF, Woodward PJ. Diagnostic imaging gynecology. 2nd Ed. Canada, Elsevier; 2015: 2-163.
4. O'Brien P, Nevastam A, Buckley AR, Chang SD, Legiehn GM. Uterine arteriovenous malformations from diagnosis to treatment. *J Ultrasound Med* 2006; 25: 1387-1392.
5. Bottomley JP, Whitehouse GH. Congenital arteriovenous malformation of the uterus demonstrated by angiography. *Acta Radiologica Diagnostica* 1975; 16: 43-48.
6. Timmerman D, Van den Bosch T, Peeraer K, Debrouwere E, Van Schoubroeck D, Stockx L, et al. Vascular malformations in the uterus: ultrasonographic diagnosis and conservative management. *Eur J Obstet Gynecol Reprod Biol* 2000; 92: 171-178.
7. Müngen E, Yergök YZ, Ertekin AA, Ergür AR, Uçmakli E, Aytaçlar S. Color doppler sonographic features of uterine arteriovenous malformations: report of two cases. *Ultrasound Obstet Gynecol* 1997; 10: 215-219.
8. Huang MW, Muradali D, Thurston WA, Burns PN, Wilson SR. Uterine arteriovenous malformations: gray-scale and doppler US features with MR imaging correlation. *Radiology* 1998; 206: 115-123.
9. Grivell RM, Reid KM, Mellor A. Uterine arteriovenous malformations: a review of the current literature. *Obstet Gynecol Surv* 2005; 60: 761-767.
10. Al-Shekaili KR, Bhatnagar G, Ramadhan FA, Al-zadjali N. Arteriovenous malformation of uterus. *Ind J Pathol Microbiol* 2011; 54: 187-188.
11. Goyal S, Goyal A, Mahajan S, Sharma S, Dev G. Acquired uterine arteriovenous malformation developing in retained products of conception: a diagnostic dilemma. *J Obstet Gynaecol Res* 2014; 40: 271-274.
12. Farias MS, Santi CC, Lima AA, Teixeira SM, De Biase TC. Radiological findings of uterine arteriovenous malformation: a case report of an unusual and life-threatening cause of abnormal vaginal bleeding. *Radiol Bras* 2014; 47: 122-124.
13. Bhoil R, Raghuvanshi V, Basavaiah S. A case of congenital uterine arterio-venous malformation managed by hysterectomy. *Pol J Radiol* 2015; 80: 202-205.
14. Hashim H, Nawawi O. Uterine arteriovenous malformation. *Malays J Med Sci* 2013; 20: 76-80.
15. Igbinedion BOE, Kurikarni S. Uterine arteriovenous malformation: A review of current literatures. *PJR* 2013; 23: 22-30
16. Kelly SM, Belli AM, Campbell S. Arteriovenous malformation of the uterus associated with secondary postpartum hemorrhage. *Ultrasound Obstet Gynecol* 2003; 21: 602-605.
17. Das C, Chaudhuri S, Karmakar M, Chakraborty S. Uterine arteriovenous malformation as a rare cause of menorrhagia. *Online J Health Allied Scs* 2008; 7: 1-4.